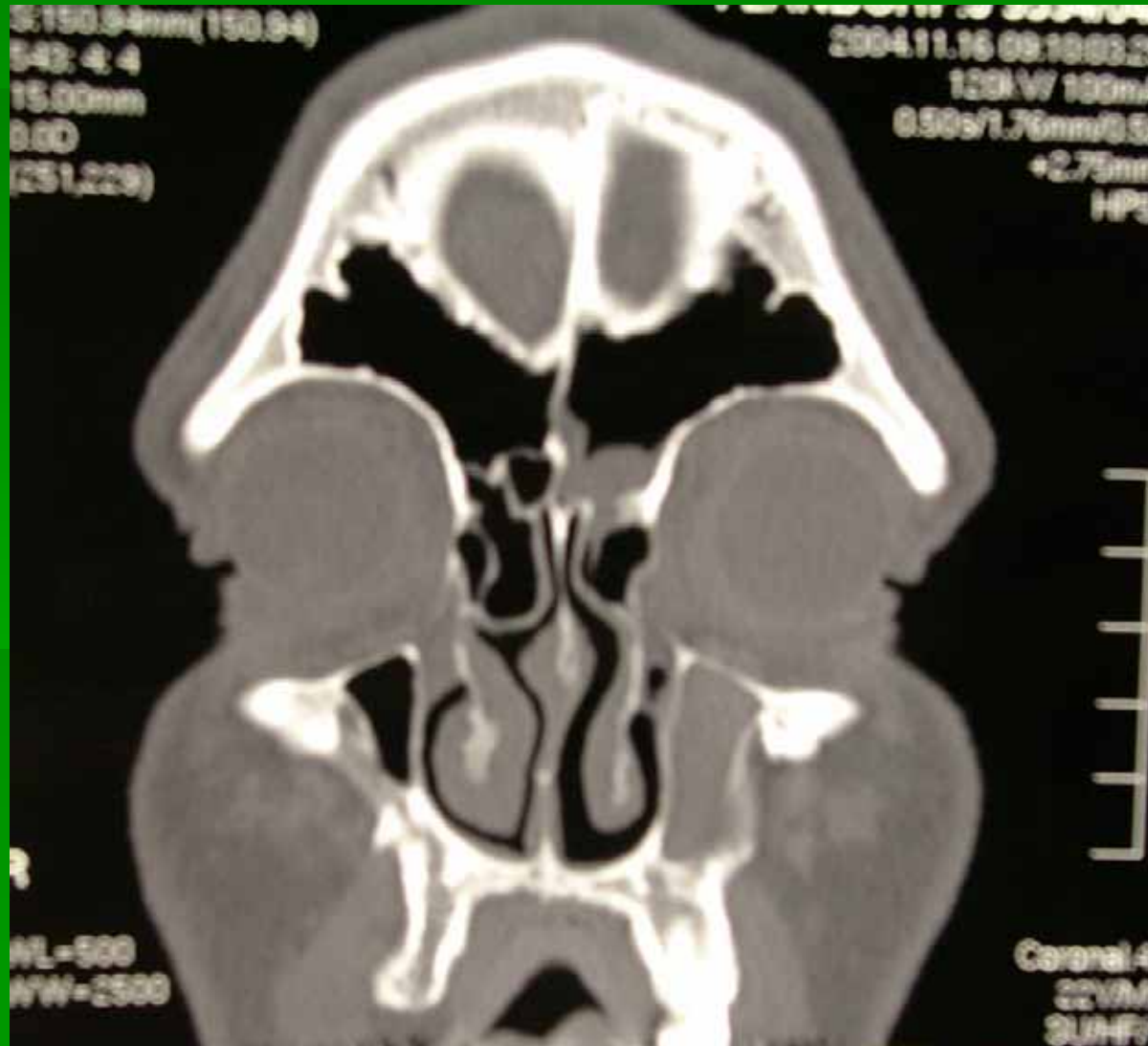

AntroChoanal Polyp Surgery

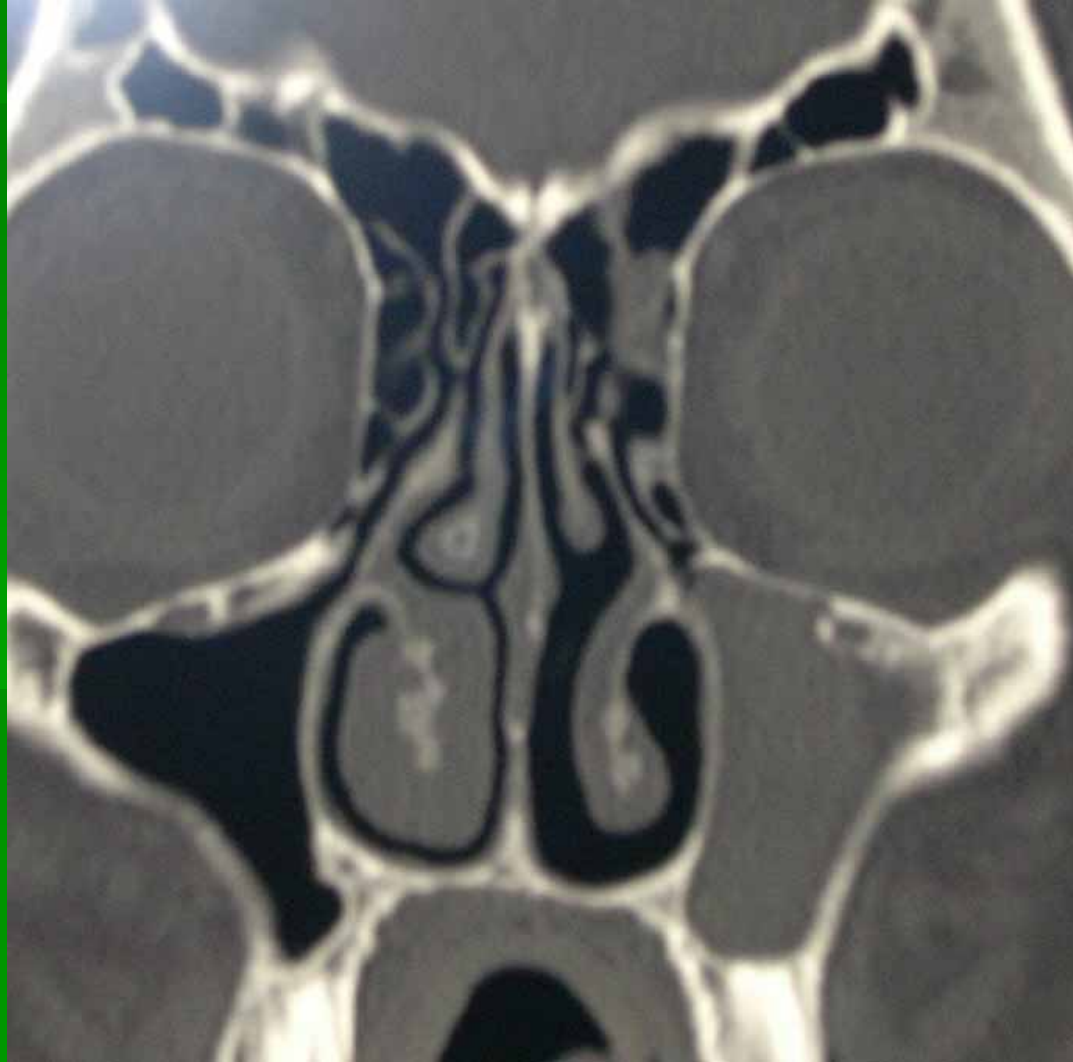**Rory Attwood
MBChB,FRCS**

**Division of Otorhinolaryngology
Faculty of Health Sciences
Tygerberg Campus, University of Stellenbosch**

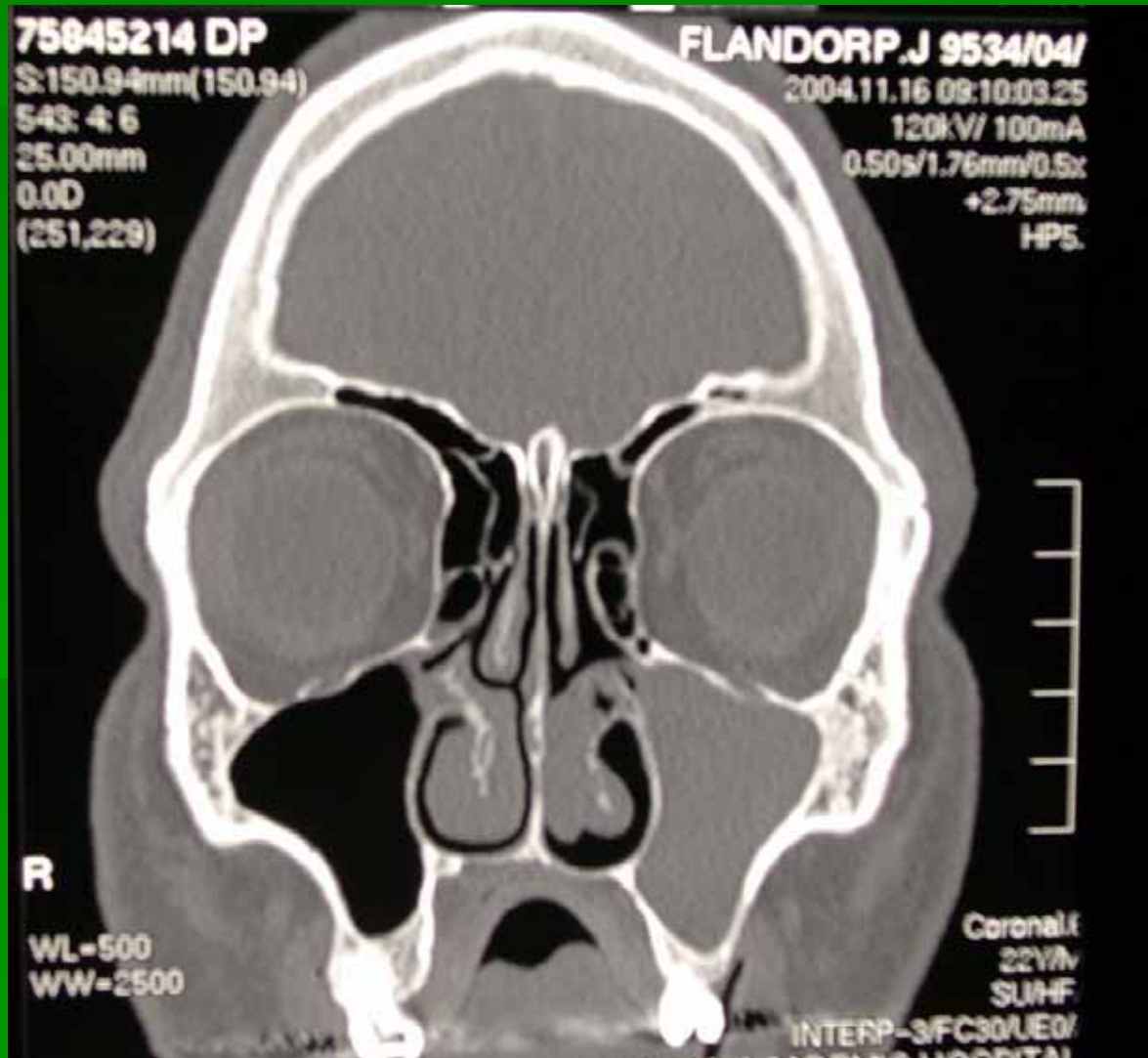
Coronal CT's



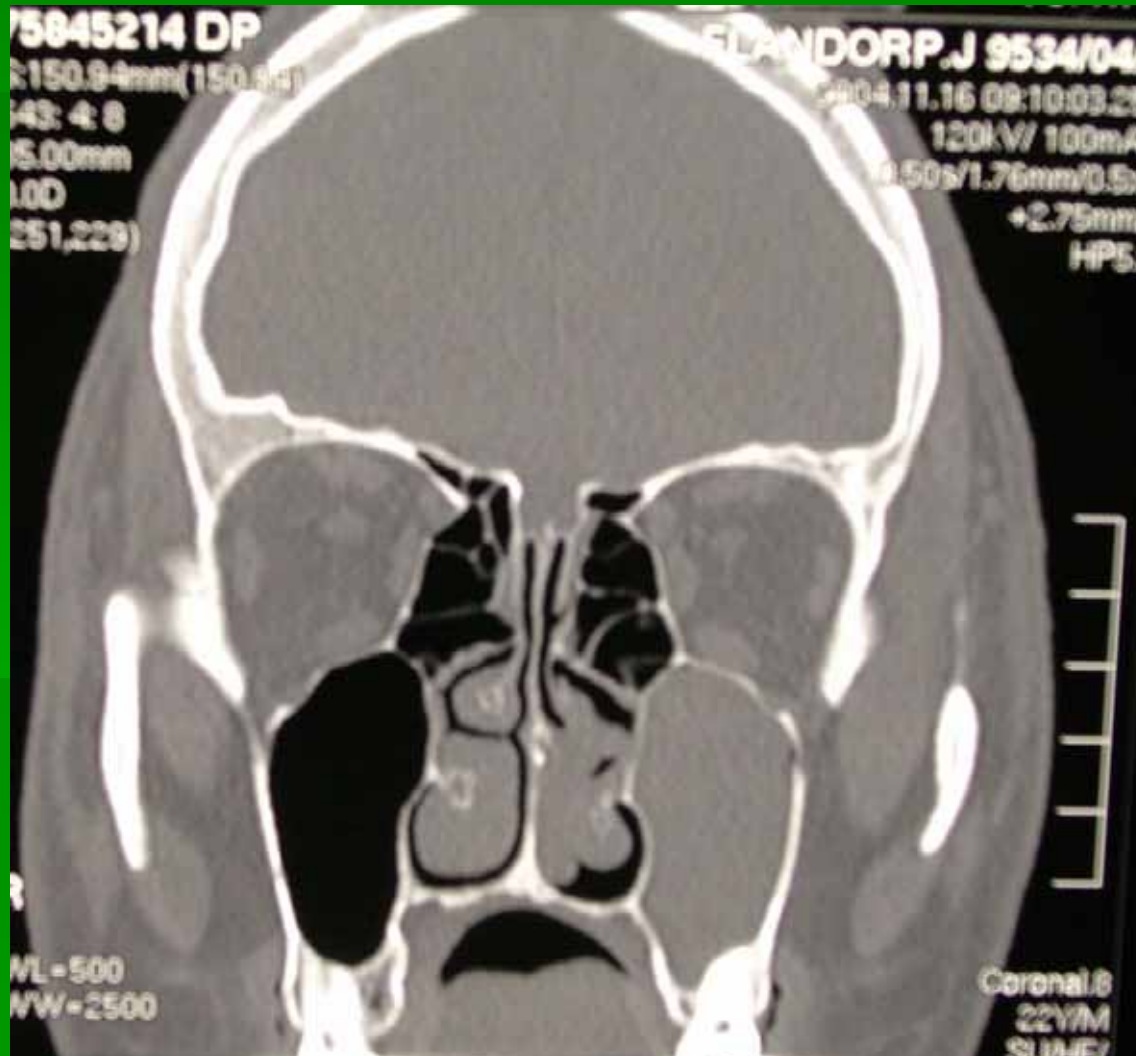
Coronal CT's



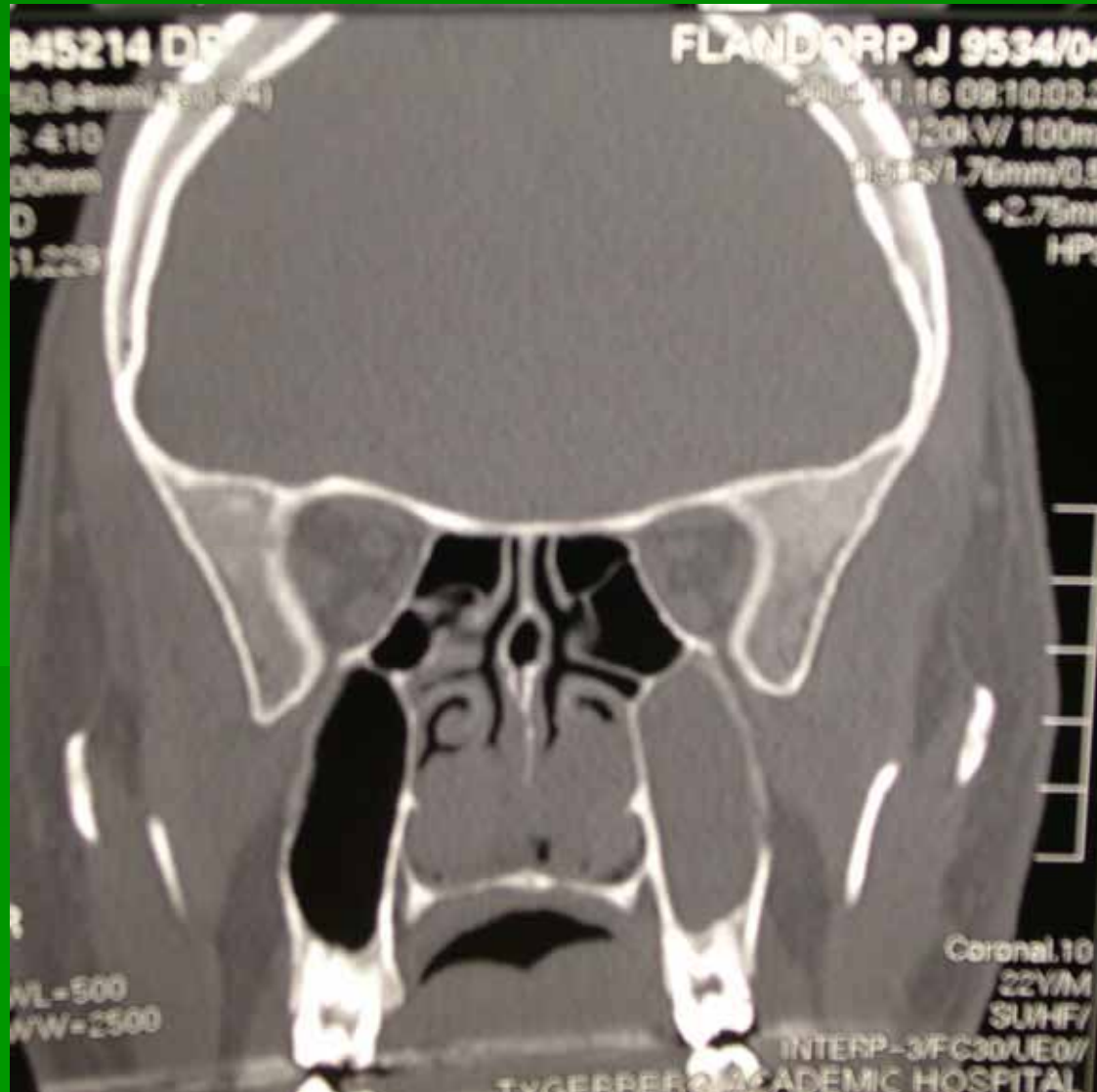
Coronal CT's



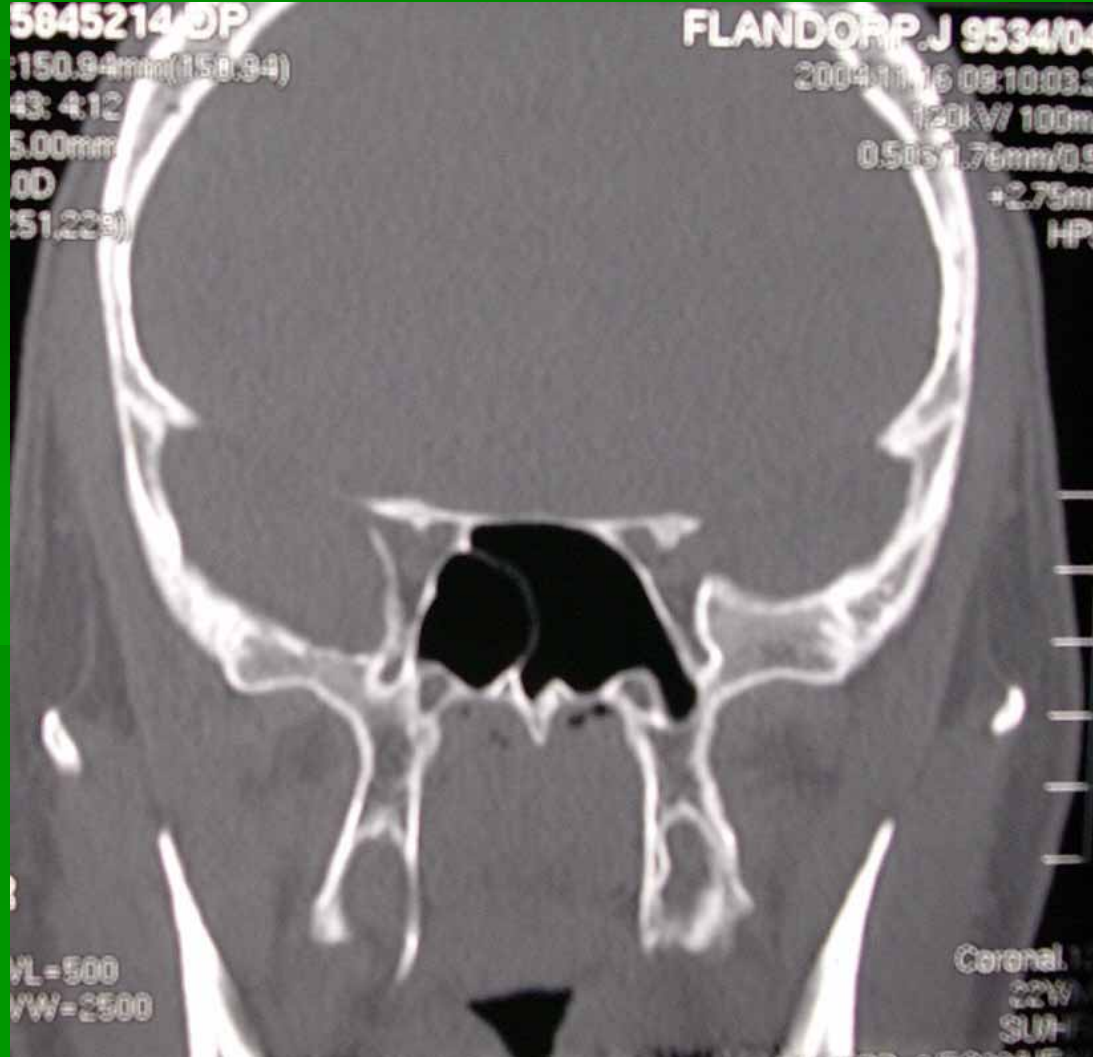
Coronal CT's



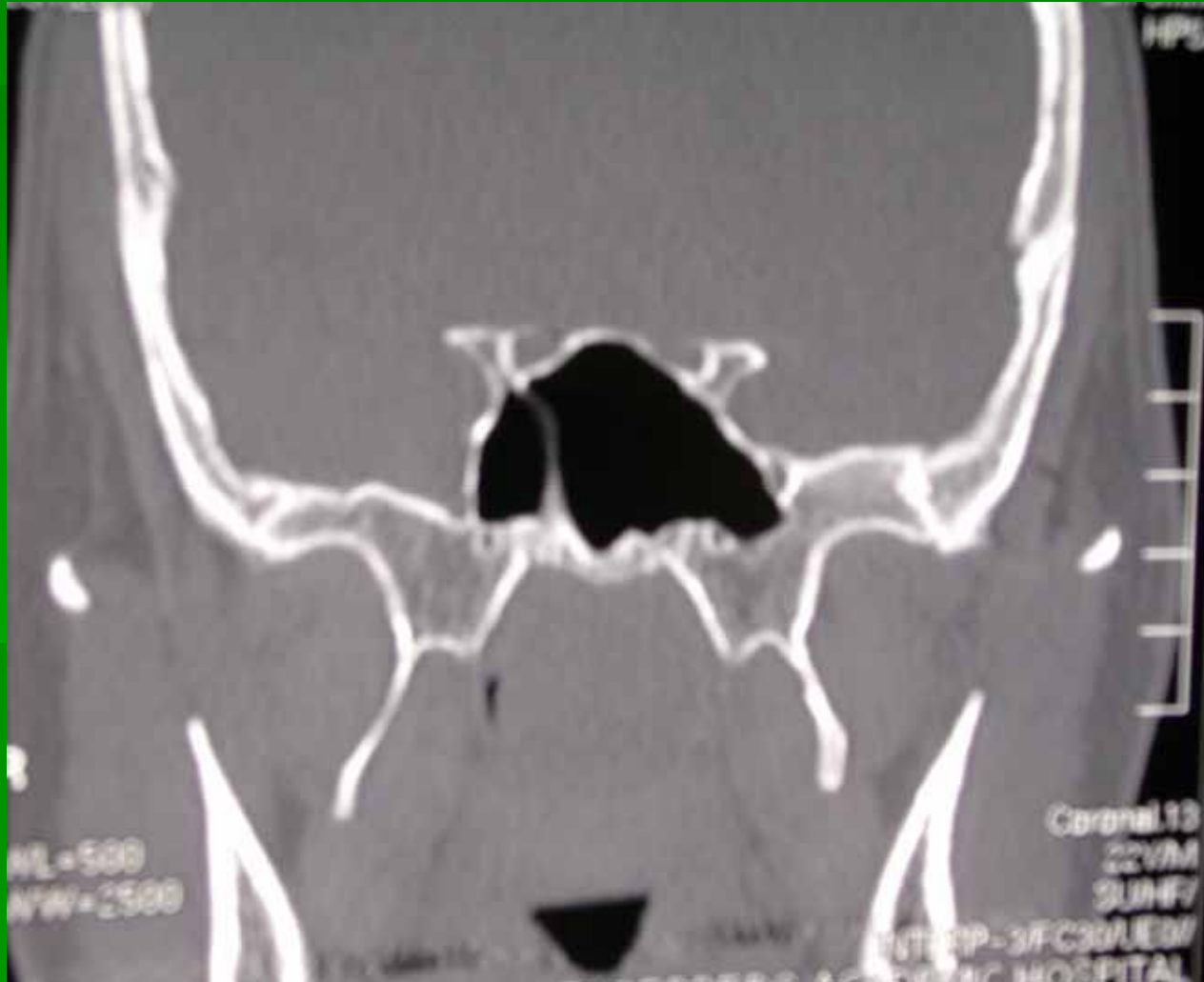Coronal CT's



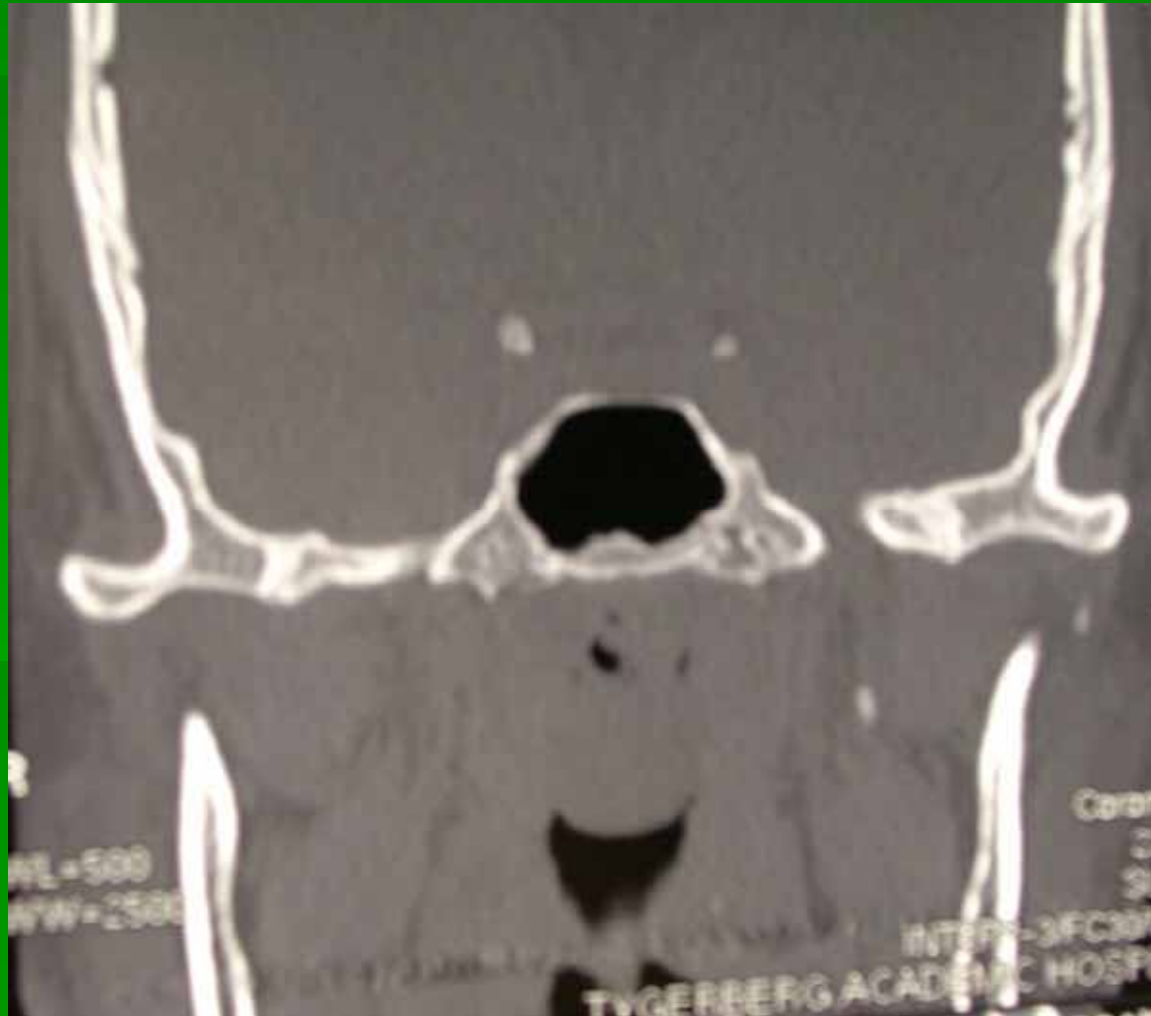
Coronal CT's



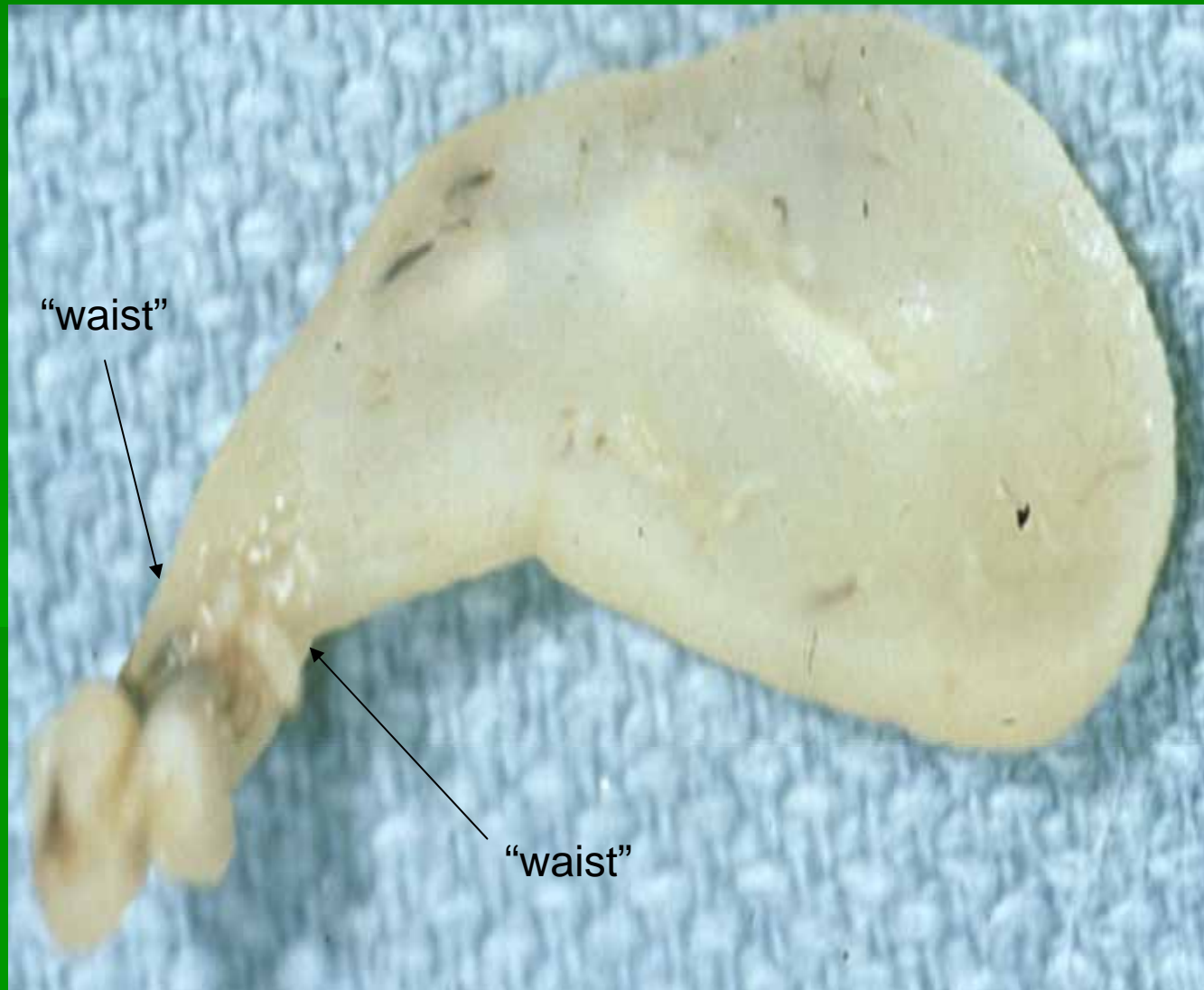
Coronal CT's



Coronal CT's

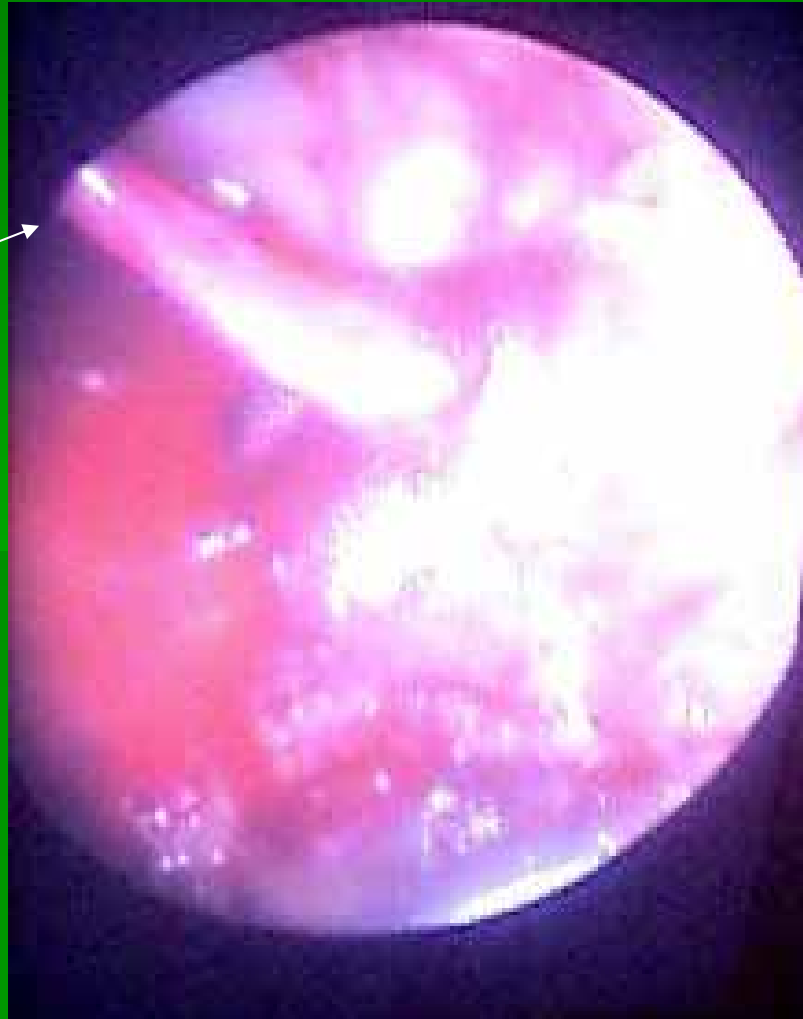

Polyp

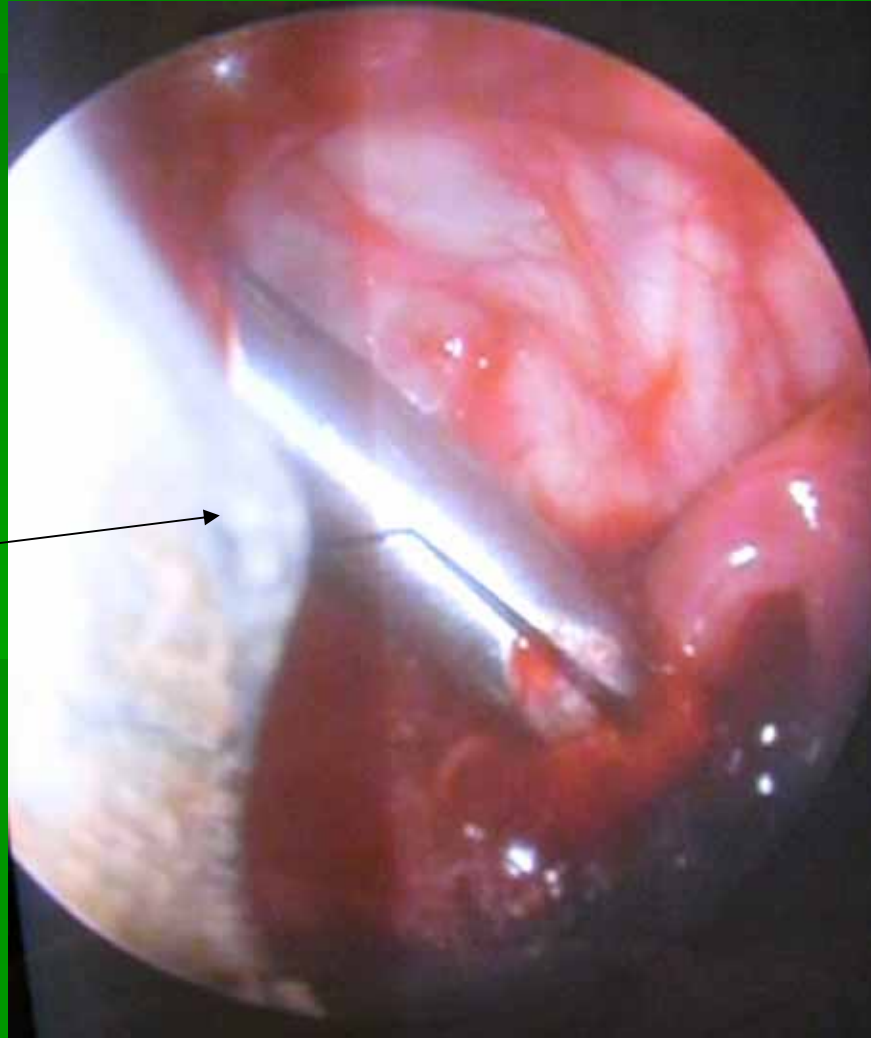


"Root" in maxillary antrum (30° scope)

ostium



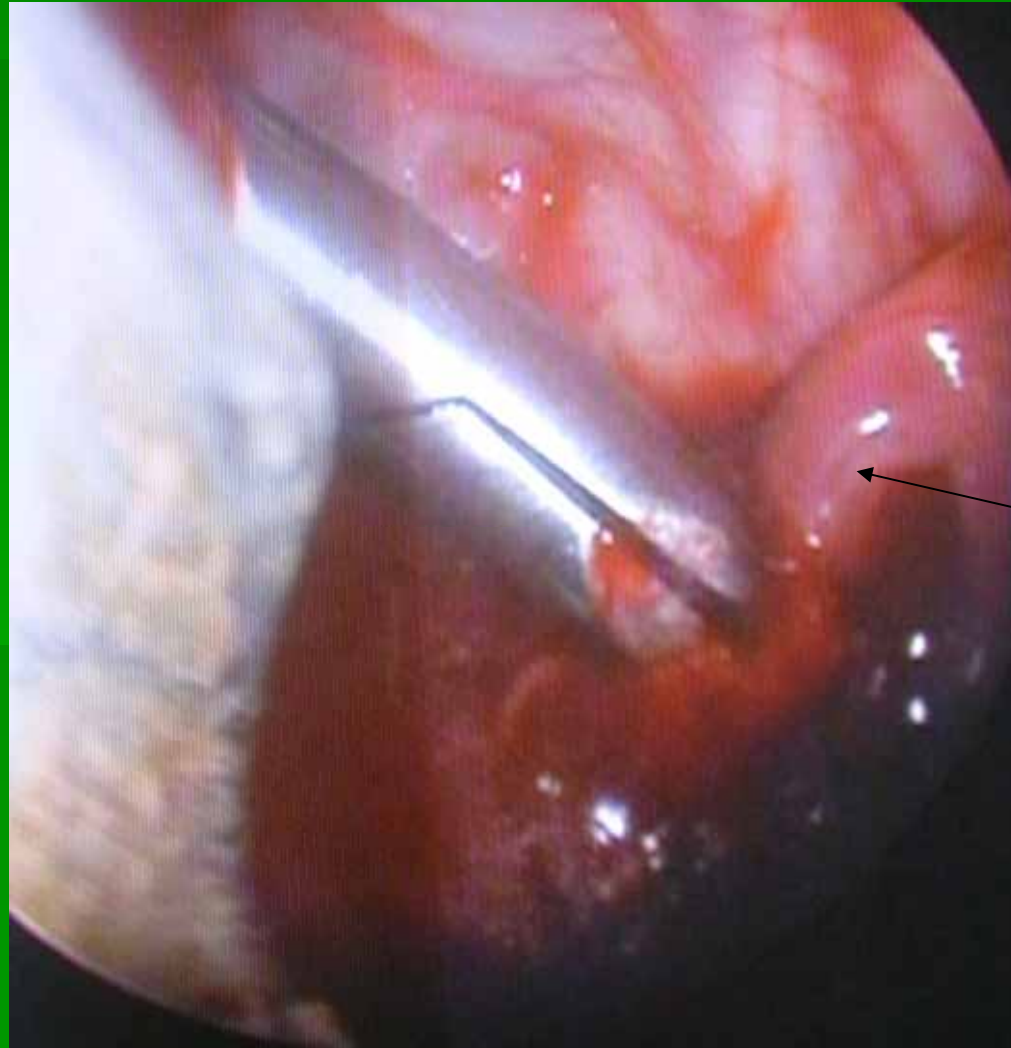
30° scope view of cyst remnant



cannula



removal of remnant



cyst
wall

removal of remnant

ostium

